

Review Article

Karate, Taekwondo, Aikido, Kung Fu, Yoga and Other Far Easter Forms of Activities - are not only Sport but also the Best Method of Treatment of Locomotor's System Deformities

Tomasz Karski¹*, Jacek Karski²

¹Department of Orthopedics and Rehabilitation, Vincent Pol University, Lublin, Poland

²Medical University, Lublin, Poland

***Corresponding author:** Tomasz Karski, Department of Orthopedics and Rehabilitation, Vincent Pol University, Lublin, Poland.
Email: tmkarski@gmail.com; t.karski@neostrada.pl

Citation: Karski T, Karski J (2017) Karate, Taekwondo, Aikido, Kung Fu, Yoga and Other Far Easter Forms of Activities - are not only Sport but also the Best Method of Treatment of Locomotor's System Deformities. Yoga Phys Ther Rehabil: YPTR-134.

Received Date: 19 August, 2017; **Accepted Date:** 20 September, 2017; **Published Date:** 27 September, 2017

Summary

Authors present an example of so called idiopathic scoliosis and the principles of treatment. According to our knowledge the cause of deformities in children, youth and pain syndromes in adults are connected not with "Weak muscles" but with 1/ the wrong position of joints of the lower or upper extremities, in the spine, in the whole trunk, 2/ with limited movement of joints, 3/ even connected with pathological position of joint, with contractures in the spine, in the hips, in the knees and in the feet. Only the proper therapy is stretching exercises like karate, taekwondo, aikido, kung fu or yoga. The authors introduced such therapy in the 70th year of XX century and all patients will receive a good result.

Keywords: Deformities in Locomotors System; Stretching; Exercises Therapy

Introduction

According to the author's experience (T. Karski, 1961-2017) deformities of the movement apparatus are caused by asymmetrical shortenings of soft tissues like tendons, fascias, capsules. Various deformities develop due to asymmetrical shortenings (in orthopedic language called "contractures") and asymmetry of movement in the joints. In etiology of the so called idiopathic scoliosis there are limited movements of the right hip, adduction (examination in the straight position of the joint), internal rotation and extension. These asymmetries are primary connected with the "Syndrome of Contractures" [SofC] (as first described this SofC Prof. Hans Mau from Tübingen, in German "Siebener Syndrom") [Literature 1-6] and according to our actual knowledge "Syndrome of Contracture and Deformities" (T. Karski, J. Karski) [Fig. 1a, 1b, 1c]. Such a point of view stays in the contrary to the opinions of many Polish and foreigner surgeons [Literature 7,8,9-23,24-28]. rehabilitation and physiotherapy doctors, who claim that all deformities in children in locomotors system are caused by "Weak muscles". They recommend the therapy called "strengthening Exercises". Unfortunately, this therapy gives only worsening results. In our point of view, it is confirmed the successful treatment will be through stretching exercises typical for yoga, karate, taekwondo, aikido and other kinds of Far Easter sports. Accuracy of our observations is proved by the presented examples of the material of so-called idiopathic scoliosis in our Out-Patients Clinics - see: www.ortopedia.karski.lublin.pl [29]

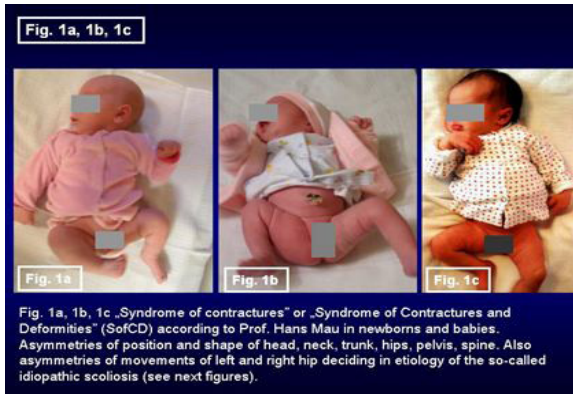

Figure 1: 1a, 1b, 1c “Syndrome of contractures” or Syndrome of Contractures and Deformities (SofCD) according to Prof. Hans Mau in newborns and babies. Asymmetries of position and shape of head, neck, trunk, hips, pelvis, spine. Also, asymmetries of movements of left and right hip deciding in etiology of the so-called idiopathic scoliosis (see next figures).

Information about the History of Discoveries of the so-called Idiopathic Scoliosis

[Literature 26,29,30-45,46]. The first observations are dated from **1984** after authors (T. Karski) scholarship in Invalid Foundation Hospital in Helsinki. Then Dr Olai Snelman (Chief of the Scoliosis Center in this Hospital) has operated many cases of scoliosis with my help as an assistant. During this time, I was trying to find the etiology of scoliosis. Unfortunately, I met no success. In the following period of ten years in Lublin, Poland during examination of scoliosis children I discovered that every child suffering from scoliosis had limited adduction of the right hip in the straight position [Fig. 2] of the joints. Additionally, some children had limited internal rotation and extension of the same joint. Therefore, I presented my first material about etiology of the so-called idiopathic scoliosis at an Orthopedic Congress in Hungary (Szeged, 1995).

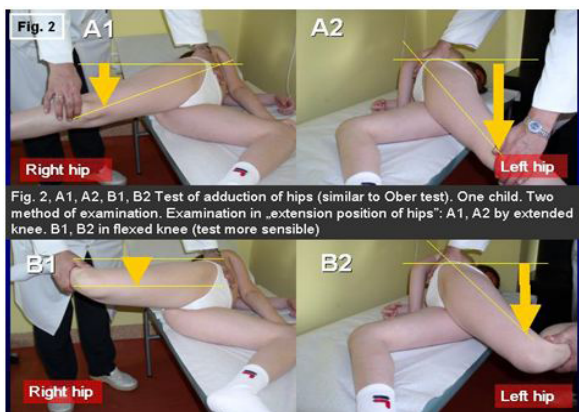


Figure 2: A1, A2, B1, B2 Test of adduction of hips (similar to Ober test). One child. Two methods of examination. Examination in „extension position of hips”: **A1, A2** by extended knee. **B1, B2** in flexed knee (test more sensible).

In **1997**, I found that all scoliosis children have the habit to stand ‘At ease’ on the right leg. Due to smaller adduction, the right hip is more stable for standing. In the years 2001 and 2004 there was an establishment of a new classification of scoliosis three groups and four types of spine deformity.

In **2006**, it was precisely described as “The Model of Hip Movements” (right hip versus the left) and as a result, the types of scoliosis. In this new classification, there are confirmed three groups and four types of scoliosis. In 2007 was described (T. Karski) the additional indirect neurological influences in the development of scoliosis, connected with Minimal Brain Dysfunctions [MBD]. Namely they are:

- extension contracture of the spine (trunk) even in babies and small children,
- Anterior tilt of the pelvis,
- general laxity of the joints. In this year (2007) I also explained why the full blind children never have scoliosis [Fig. 3].

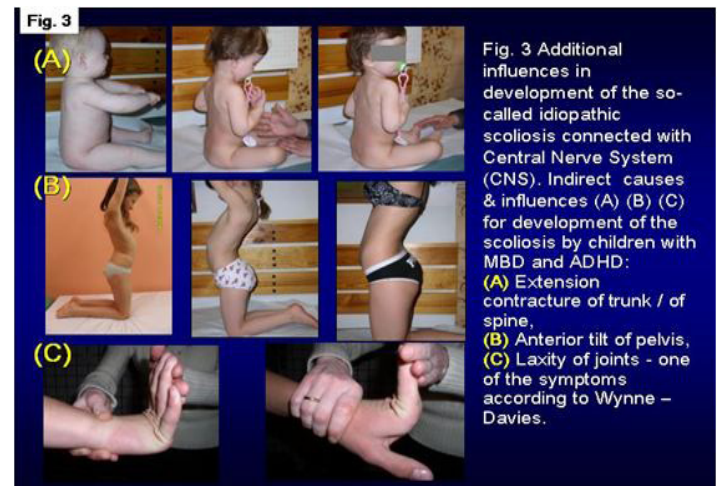

Figure 3: Additional influences in development of the so-called idiopathic scoliosis connected with Central Nerve System (CNS). Indirect causes & influences (A) (B) (C) by children with MBD and ADHD: **(A)** Extension contracture of trunk / of spine, **(B)** Anterior tilt of pelvis, **(C)** Laxity of joints - on picture one of the symptoms according to Wynne - Davies.

Material we observe together more that 3000 patients in the period of 32 years. The patients were in the ages of 4 to 77 years. The control group were 360 patients coming to us with suspicion of scoliosis, but in this group the range of movement of hips were symmetrical and sufficient large and there were no spinal curves.

New classification, important in planning of therapy and prophylaxis [Fig. 4, 5, 6, 7]. The new classification is based on

- biomechanical influences in development of scoliosis – gait and standing,

- b) on model of hips movement and
 c) and is connected with age of children. In the examination, we use Adams test or Lublin test [Figure 8].

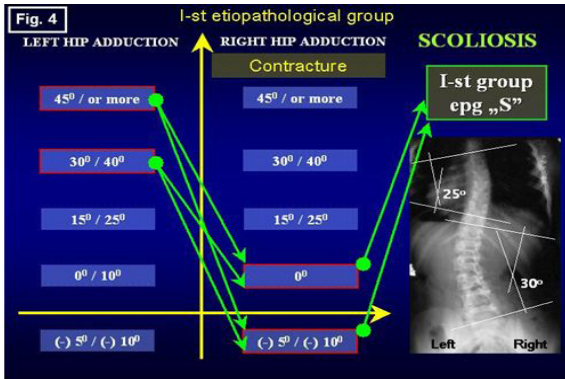


Figure 4: Classification of scoliosis. I-st etiopathological group (epg) „S” scoliosis. Specific model of hips movements

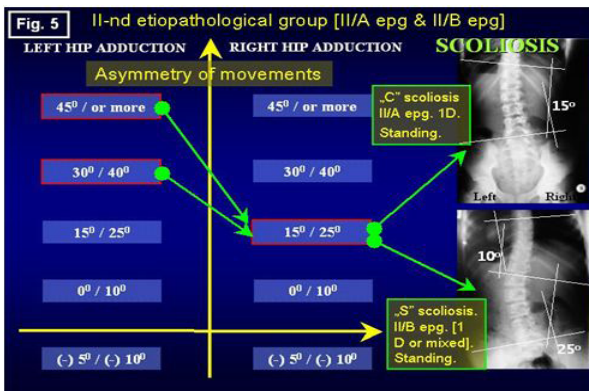


Figure 5: Classification of scoliosis. II-nd etiopathological group - “C” scoliosis II/A epg & “S” scoliosis II/B epg. Specific model of hips movements.

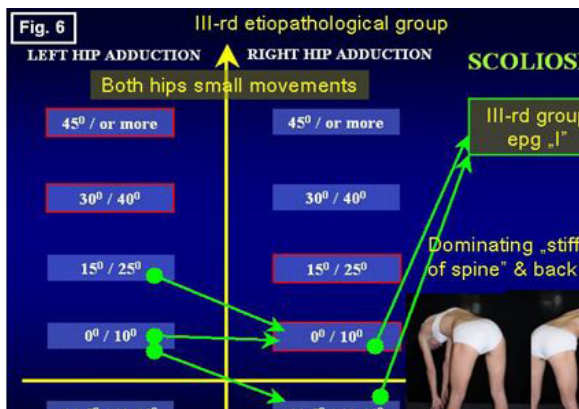


Figure 6: Classification of scoliosis. III-rd etiopathological group – “T” spine deformity. Stiffness of spine. No curves or small. Specific model of hips movements.

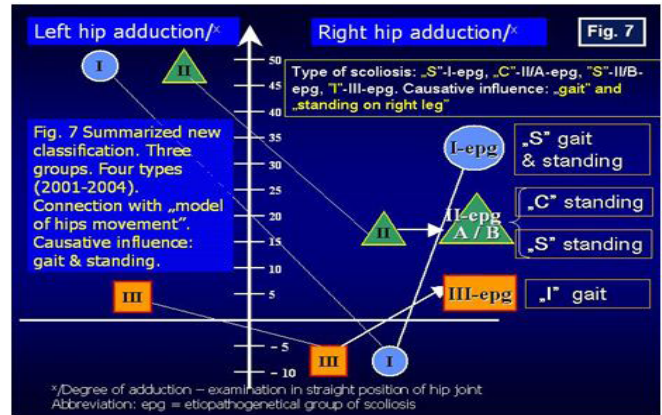


Figure 7: Summarized new classification. Three groups. Four types (2001-2004). Connection with “Model of hips movement”. Causative influence: gait & standing ‘At ease’ on the right leg.

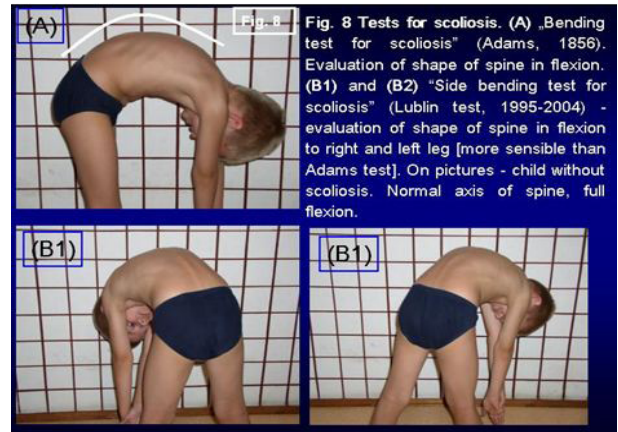

Figure 8: Tests for scoliosis. (A) “Bending test for scoliosis” (Adams, 1856). Evaluation of shape of spine in flexion. (B1) and (B2) “Side bending test for scoliosis” (Lublin test, 1995-2004) - evaluation of shape of spine in flexion to right and left leg [more sensible than Adams test]. On pictures - child without scoliosis. Normal axis of spine, full flexion. Every type of scoliosis starts to develop in age of 2 - 3years. In this age of children, we should start with therapy and causal prophylaxis.

First group of the ‘so-called’ idiopathic scoliosis (“S” double scoliosis, I etiopathological [epg]). Hips right / left model of movements: big limitation of movement of the right hip, especially limited the adduction and internal rotation (examination in the straight position of the joint) and the full movement of the left hip. Scoliosis develop because of permanent standing ‘At Ease’ on the right leg and also during the gait. In every step the necessary movement in the right hip, when was not possible, was created as a compensatory movement in the pelvis and in the spine. Therefore, deformities of the spine occur. The first symptoms are rotation deformity, permanent distortion of inter-vertebral joints and in result stiffness of thoracic and lumbar parts of the spine.

Here, in this point, I can explain - the gait of blind children is without any lifting of legs and pelvis so compensatory movement of the pelvis and spine does not exist and the scoliosis do not develop. Also standing of these persons is with carefully attention and symmetrical on both feet (observation of ophthalmologist Dr Jolanta Karska). Characteristic of "S" scoliosis I epg group are: two curves, lumbar left convex, thoracic right convex, stiffness of spine and rib hump on the right side. This type of scoliosis is characterized by a very large progression, especially in acceleration period of growth.

Second group of the 'so-called' idiopathic scoliosis ("C" II/a epg - one curve scoliosis, or "S" II/b epg - double curve scoliosis). Hips right / left model of movements: partially limited adduction movement of the right hip and the full movement of the left hip. Scoliosis - "C" II/a epg - one curve deformity develops because of permanent standing 'at ease' on the right leg. In scoliosis "S" - II/b epg - double curve, additionally, regardless to the habit of standing 'at ease' on the right leg, exists laxity of joints or / and wrong, incorrect previous therapy. In the both types of scoliosis "C" II/a epg and "S" II/b epg - the spine is flexible, progression of the spine deformity is very small. At adults, very often, this type of scoliosis became to be "degenerative scoliosis" with permanent pain syndromes.

Third group of 'so-called' idiopathic scoliosis ("I" scoliosis III epg). Hips right / left model of movements: significantly limited movement of the right hip and very limited movement of the left hip. The cause of the scoliosis is the gait only. The characteristics of this type of scoliosis are: stiffness of the spine, small or no-existing curve, no progression. This type of spine deformity over many years was never been included to the scoliosis group. In new classification - stiff spine is also "special type of scoliosis" (T. Karski, J. Karski, 1995 -2017).

Former Therapy of Scoliosis. Because the etiology of scoliosis has been a secret for over two thousand year, all scientists present the opinion, that the scoliosis is caused by "weak muscles" giving insufficient stabilization of the spine. In therapy, they recommended only strengthening exercises for muscles, next corset and on end of the therapy - surgery. After these improper (we known now) exercises the curves were bigger, the rib hump wider, the stiff spine more rigid. When the parents ask the doctor why the result of the therapy is not good or even completely bad - they answered: "it is natural history of scoliosis". Next they say - yes, the result is bad - and it is normal, but now the child will receive corset and in the future the surgery will be necessary. No - our experience (T. Karski & J. Karski) has shown that the former exercises were completely incorrect and totally wrong. The proper therapy is only by stretching exercises rejecting the contracture (limitation of movements) in region of the hips and of the whole spine [Fig. 9, 10a, 10b, 11a, 11b, 1c, 11d, 12a, 12b, 13]. Only such methods of the therapy give good results. We have confirmed on large material that stretch-

ing exercises are very beneficial not only in therapy but specially in causal prophylaxis of the so-called idiopathic scoliosis. In the therapy and in the prophylactics the best are such sports - like karate, taekwondo, aikido, kung fu, yoga [Fig. 14, 15, 16, 17, 18].

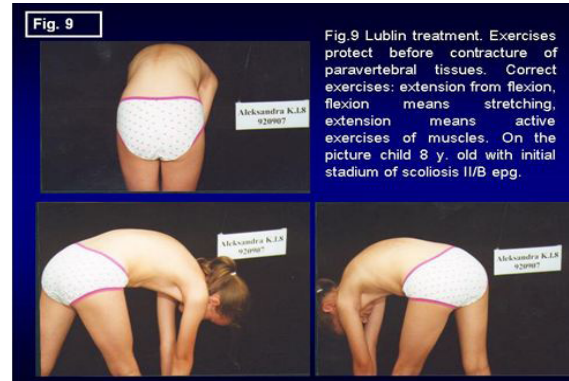


Figure 9: Lublin treatment. Exercises protect before contracture of paravertebral tissues. Correct exercises: extension from flexion, flexion means stretching, extension means active exercises of muscles. On the picture child 8 y. old with initial stadium of scoliosis II/B epg.

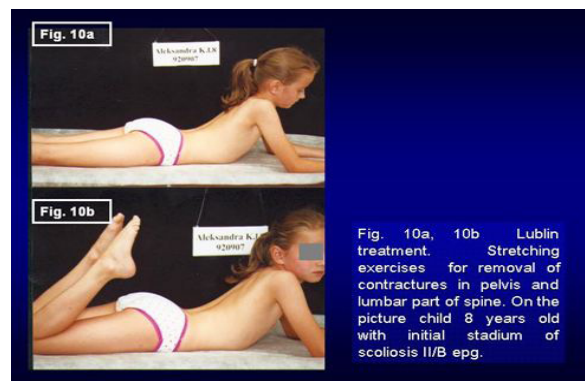


Figure 10: 10a, 10b Lublin treatment. Stretching exercises for removal of contractures in pelvis and lumbar part of spine. On the picture child 8 years old with initial stadium of scoliosis II/B epg.

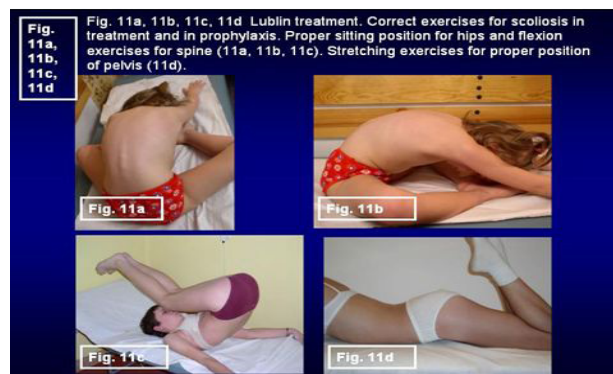

Figure 11: 11a, 11b, 11c, 11d Lublin treatment. Correct exercises for scoliosis in treatment and in prophylaxis. Proper sitting position for hips and flexion exercises for spine (11a, 11b, 11c). Stretching exercises for proper position of pelvis (11d).

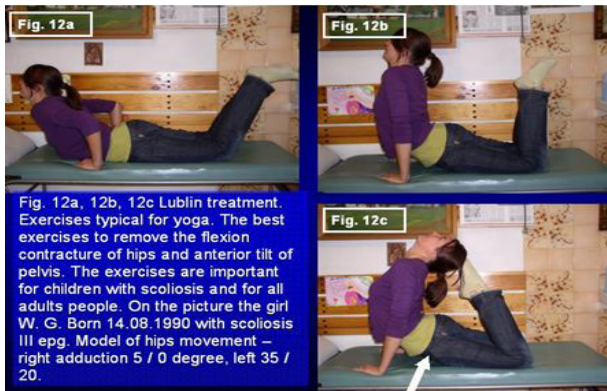


Figure 12: 12a, 12b, 12c Lublin treatment. Exercises typical for yoga. The best exercises to remove the flexion contracture of hips and anterior tilt of pelvis. The exercises are important for children with scoliosis and for all adults people. On the picture the girl W. G. Born 14.08.1990 with scoliosis III epg. Model of hips movement – right adduction 5 / 0 degree, left 35 / 20 degrees.

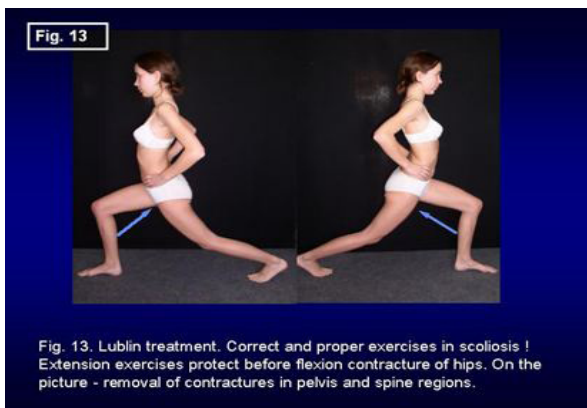

Figure 13: Lublin treatment. Correct and proper exercises in scoliosis! Extension exercises protect before flexion contracture of hips. On the picture - removal of contractures in pelvis and spine regions.



Figure 14: Lublin therapy. Yoga, Karate, Tekwondo, Aikido, Kung Fu - proper exercises in program of treatment and prophylaxis of scoliosis and other deformities in locomotors system.



Figure 15: The treatment by Karate, Tekwondo, Aikido, Kung Fu - in program of therapy and prophylaxis of scoliosis, as well incorrect posture of pelvis and shoulders, flexion contracture of knees, equines position of feet. With such therapy we should start in age of 4-5 years of a child.



Figure 16: Yoga, Karate, Tekwondo, Aikido, Kung Fu - proper exercises in program of treatment and prophylaxis of scoliosis and others deformity of locomotors system. On the pictures exercises for spine and against flexion contracture of hips.



Figure 17: Yoga, Karate, Tekwondo, Aikido, Kung Fu - proper exercises in program of treatment and prophylaxis of scoliosis and others deformity of locomotors system. On the pictures rotation and deviation exercises for spine and for abduction of hips.



Figure 18: Yoga, Karate, Tekwondo, Aikido, Kung Fu - proper exercises in program of treatment and prophylaxis of scoliosis and others deformity of locomotors system. On the pictures the exercises for flexion of spine.

Karate, taekwondo, aikido, yoga in treatment of the so-called idiopathic scoliosis. Both authors in the period of 32 years (T. Karski) and 22 years (J. Karski) have the occasion to observe the excellent result after treatment by stretching exercises typical for these Far Eastern Sport Arts. Only one condition is very important – we should start with the new therapy very early, before fixation of deformity, before anatomical changes of spinal bodies, in arches, in processes spinosi, transversal and articularis. The best time to beginning the therapy is 4-5 year of life.

Explanation of the Method of Therapy and Prophylaxis.

The aim of the therapy is to overcome the insufficient adduction of the right hip or even abduction contracture (in I epg and III epg group of scoliosis). It is possible by stretching exercises – for example, identical like in yoga. The yoga exercises are made very gently, long lasting of each stretching position, repeated very gently and many times. The treated child, as result of the therapy, receive adduction, full internal rotation and also extension of the right hip. Other exercises give full flexion, deviation and full rotation movement of spine. “Free from contractures” hips, pelvis and spine guarantees the proper growth of the spine. On the pictures, we present these all exercises (Figure 14, 15, 16, 17, 18).

Discussion

Authors treat children with scoliosis by these stretching exercises from 1984. Also, many other deformations in children can be treated by the stretching exercises. Cases for such a therapy are following: 1/ torticollis (wry neck), 2/ equines deformity of feet, 3/ anterior tilt of pelvis with hiperlordosis of lumbar spine, 4/ valgus deformity of knees and many others.

Here we want to emphasize and confirm that yoga in the treatment and in the prophylaxis is very profitable. What is characteristic for yoga, is that the exercises are done very gently, they

are repeated many times, the “Corrected position” is hold for a long time. This is a great time for “meditation”, and in Christian Countries like Poland it is the excellent time to think about God, about Jesus Christ and Saint Mary, as well about “Health thanks proper exercises”.

Conclusion

1. The deformations and wrong position of the body of children and pain syndromes of the adults are caused by asymmetrical shortening of soft tissues - tendons, muscles, fascias, capsules, called in orthopedics “contractures”, but not because of “weak muscles”.
2. These contractures are the cause of the asymmetric growth and various deformations like scoliosis, wry neck, equines deformity of feet, contractures of knees and many others.
3. Our observations confirm that without any doubt the “weak muscles” are not the cause of deformations of children and youth as well, pain syndromes in adults. Unfortunately, the diagnosis of “weak muscles” is very often given / stated by Polish physiotherapist and rehabilitations doctors.
4. The cause of the so-called idiopathic scoliosis is “contractures” or only partially limited movement of the right hip giving influence for asymmetrical growth of spine due to function.
5. This function is “walking” and standing ‘at ease’ on the right leg.
6. Every type of spine deformity starts to develop in age of 2-3 years.
7. The only proper therapy are the stretching exercises typical for karate, taekwondo, aikido, kung fu, yoga.

Acknowledgment. Many thanks for Honorata Menet and for Mr. David Poynton for proper Edition of English text.

Literature

1. Green NE, Griffin PP (1982) Hip dysplasia associated with abduction contracture of the contralateral hip. *J.B.J.S* 63: 1273-1281.
2. Heikkilä E (1984) Congenital dislocation of the hip in Finland. An epidemiologic analysis of 1035 cases, *Acta Orthop. Scandinavica* 55: 125-129.
3. Hensinger RN (1979) Congenital dislocation of the hip. *Clinical Symp* 31.
4. Howorth B (1977) The etiology of the congenital dislocation of the hip, *Clin. Orthop* 29: 164-179.
5. James W Ogilvie, John Brown, VeeAnn Argyle, Lesa Nelson, Mary Meade et al. (2006) The search for Idiopathic Scoliosis Genes, *Spine* 31: 679-681.
6. Karski T. Kontraktoren und Wachstumsstörungen im Hüft- und Beckenbereich in der Ätiologie der sogenannten “Idiopathischen Skoliosen” - biomechanische Überlegungen, *Orthop. Praxis*, 3/96, 32:155-160

7. Burwell G, Dangerfield PH, Lowe T, Margulies J (2000) Spine. Etiology of Adolescent Idiopathic Scoliosis: Current Trends and Relevance to New Treatment Approaches 14..
8. Dangerfield PH, Dorgan JC, Scott D, Gikas G, Taylor JF (1995) Stature in Adolescent Idiopathic Scoliosis (AIS). 14 Meeting EPOS, Brussels: 210.
9. Lowe TG, Lawellin D, Smith DAB, Price C, Haheer T, et al. (2002) Platelet calmodulin levels in adolescent idiopathic scoliosis. *Spine* 2002; 27:768-775.
10. Malawski S. Własne zasady leczenia skolioz niskostopniowych w świetle współczesnych poglądów na etiologię i patogenezę powstawania skolioz, *Chir. Narz. Ruchu i Ortop. Pol.*, 1994, 59, 3:189-197
11. Mau H (1979) Zur Ätiopathogenese von Skoliose, Hüftdysplasie und Schiefhals im Säuglingsalter. *Zeitschrift f. Orthop* 5: 601-605.
12. Mau H (1982) Die Ätiopathogenese der Skoliose, Bücherei des Orthopäden, Band 33, Enke Verlag Stuttgart 1: 110
13. McMaster MJ (1983) Infantile idiopathic scoliosis: can it be prevented? *J. B. J. S* 65: 612-617.
14. Meyer in Tomaschewski R, Popp B (1992) Die Funktionelle Behandlung der beginnenden idiopathischen Skoliose. *Jahann Ambrosius Barth, Leipzig Heidelberg*: 1-96.
15. Normelly H (1985) Asymmetric rib growth as an aetiological factor in idiopathic scoliosis in adolescent girls, *Stockholm* 1-103.
16. Oleszczuk J, Chazan B, Kamiński K, Leszczyńska-Gorzela B, Skreń A, et al. (1999) "Poród patologiczny" in "Położnictwo" Klimek Rudolf, Dream Publ. Comp.Inc., Kraków 291-337
17. Oleszczuk J, Szymański W, Wilczyński (1999) "Patologia ciąży" in "Położnictwo" Klimek Rudolf, Dream Publ. Comp.Inc., Kraków 395-499
18. Robinson CM, McMaster MJ (1996) Juvenile idiopathic scoliosis. Curve patterns and prognosis in one hundred and nine patients, *J. B. J. S* 78: 1140-1148.
19. Saji M, Leong JCY, Upadhyay SS (1995) Increased femoral neck-shaft angles in adolescent idiopathic scoliosis. *Spine* 20: 303-311.
20. Sevastik J, Diab K (1997) *Studies in Technology and Informatics, Research into Spinal Deformities 1*, 37, IOS Press Amsterdam, Berlin, Oxford, Tokyo, Washington, DC 1-509.
21. Skogland LB, Miller A (1980) Growth related hormones in idiopathic scoliosis. An endocrine basis for accelerated growth, *Acta Orthop. Scandinavica* 51: 779-789.
22. SkwarczA, Rejzner C, BednarekA, Repelewski M (1984) Epidemiologia bocznych skrzywień kręgosłupa w makroregionie środkowo – wschodnim. Opracowanie zbiorowe pod red. Prof. W. Degi „Współczesne wykrywanie i zapobieganie progresji bocznych skrzywień kręgosłupa”, *PZWL* 20 - 21
23. Stokes IAF (1992) *Studies in Technology and Informatics, Research into Spinal Deformities 2*, 59, IOS Press 1999, Amsterdam, Berlin, Oxford, Tokyo, Washington DC, 1-385.
24. Tomaschewski R, Popp B (1992) Die Funktionelle Behandlung der beginnenden idiopathischen Skoliose. *Jahann Ambrosius Barth, Leipzig Heidelberg*: 1-96.
25. Tylman D (1995) *Patomechanika bocznych skrzywień kręgosłupa*, Wydawnictwo Severus, Warszawa: 167.
26. Vlach O, Rouchal T, Neubauer M (2003) Skoliozy tzw. idiopatyczne – etiologia, rozpoznawanie zagrożeń, nowe leczenie rehabilitacyjne, profilaktyka. The etiology of the so-called idiopathic scoliosis. The new rehabilitation treatment. *Prophylaxis, FOLIUM, Lublin* 1-233
27. Zarzycki D, Skwarcz A, Tylman D, Pucher A (1992) Naturalna historia bocznych skrzywień kręgosłupa, *Chir. Narz. Ruchu i Ortop. Polska* 57: 9-15
28. Żuk T, Dziak A (1993) *Ortopedia z traumatologią narządów ruchu*, PZWL, Warszawa: 161-173
29. www.ortopedia.karski.lublin.pl.
30. Karski T. Skoliozy tzw. idiopatyczne – przyczyny, rozwój i utrwalanie się wady. Profilaktyka i zasady nowej rehabilitacji. The etiology of the so-called idiopathic scoliosis. Progress and fixation of the spine disorders. The prophylaxis and principles of the new rehabilitation treatment, *KGM, Lublin*, 2000, 1 - 143
31. Karski T, Karski J, Madej J, Latalski M. Persönliche Überlegungen zur Ätiologie der idiopathischen Skoliosen. Praktische Hinweise zur Entdeckung beginnender Skoliosen. Prinzipien der neuen Übungstherapie. Möglichkeiten der Prophylaxe. *Orthop. Praxis*, 02/2002, 38, 75 – 83
32. Karski T. "Skoliozy tzw. idiopatyczne - etiologia, rozpoznawanie zagrożeń. Nowa klasyfikacja (2001 – 2004/2006). Nowe leczenie rehabilitacyjne. Profilaktyka. The etiology of the so-called idiopathic scoliosis. New classification (2001 – 2004/2006). The new rehabilitation treatment. Prophylaxis. Ätiologie der sogenannten idiopathischen Skoliosen. Drei pathogenetische Gruppen, vier Typen der Wirbelsäuledeformitäten. Neu Übungstherapie. Prophylaxe". (Book about scoliosis in Polish, English and in German), Printed / *Drukarnia KGM, Poland / Lublin*, 2011, pages 420
33. Karski T, Makai F, Rehak L, Karski J, Madej J, Kałakucki J (2001) The new Rehabilitation treatment of so-called idiopathic scoliosis. The dependence of results on the age of children and the stage of deformity. *Locomotor System* 8: 66-71
34. Karski T (1997) Biomechanical influence onto the development of the so-called "idiopathic scoliosis" - clinical and radiological symptoms of the disorder. *Acta Orthopaedica Yugoslavica* 28: 9-15
35. Karski T (1998) The rehabilitation exercises in the therapy and prophylaxis of the so-called "idiopathic scoliosis", *Acta Orthopaedica Yugoslavica* 29: 5-9.
36. Karski T (2000) in Burwell, Dangerfield - Spine. Etiology of Adolescent Idiopathic Scoliosis: Current Trends and Relevance to New Treatment Approaches, Volume 14/Number 2, Hanley & Belfus, Inc, Philadelphia: 324
37. Karski T (2002) Etiology of the so-called "idiopathic scoliosis". Biomechanical explanation of spine deformity. Two groups of development of scoliosis. New rehabilitation treatment. Possibility of prophylactics, *Studies in Technology and Informatics, Research into Spinal Deformities 91*: IOS Press Amsterdam, Berlin, Oxford, Tokyo, Washington DC, 37-46.
38. Karski T (2002) in Grivas TB. *Studies in Technology and Informatics, Research into Spinal Deformities 4*, 91 IOS Press Amsterdam, Berlin, Oxford, Tokyo, Washington DC: 37-46.

39. Karski T (2005) Biomechanical Explanation of Etiology of the So-Called Idiopathic Scoliosis. Two etiopathological Groups - Important for Treatment and Neo-Prophylaxis *Pan Arab Journal* 9: 123-135.
40. Tomasz Karski, Jaroslaw Kalakucki, Jacek Karski (2007) Relationship of "syndrome of contractures" in newborns with the development of the so-called idiopathic scoliosis (1991) (*WJP*) *World Journal of Pediatric* 4: 254-259
41. Karski T (2010) Explanation of biomechanical etiology of the so-called idiopathic scoliosis (1995 – 2007). New clinical and radiological classification" in "Pohybove Ustroji" [*Locomotor System*] 17: 26-42 (Czech Republic - 2010)
42. Karski Tomasz (2010) Factores biomechanicos en la etiologia de las escoliosis dinominadas idiopaticas. Nueva clasificacion. Nuevos test clinicos y nueavo tratamiento conservador y profilaxis", *Cuestiones de Fisioterapia*, Mayo-Agosto 39: 85-152.
43. Karski Tomasz (2010) Biomechanical Etiology of the So-called Idiopathic Scoliosis (1995-2007). New Classification: Three Groups, Four Sub-types. Connection with „Syndrome of Contractures”, *Pan Arab J. Orthop. Trauma* 14.
44. Karski T (2011) Biomechanical Etiology of The So-Called Idiopathic Scoliosis (1995 – 2007) – Connection with "Syndrome of Contractures" – Fundamental Information for Pediatricians in Program of Early Prophylactics / *Journal of US-China Medical Science, USA* 8.
45. Komprda J (2002) Etiology of the so-called "idiopathic scoliosis". Biomechanical explanation of spine deformity. Two groups of development of scoliosis. New rehabilitation treatment. Possibility of prophylactics, *Studies in Technology and Informatics, Research into Spinal Deformities* 4, 91, IOS Press Amsterdam, Berlin, Oxford, Tokyo, Washington DC, 37-46.
46. Tarczyńska M, Karski T, Frelek-Karska M (2000) Prenatal conditions for the development of the hip dysplasia in the material of 223 pregnant women, followed-up study of the newborn children". *EPOS 2000, XIX Meeting of the European Pediatric Orthopaedic Society, Congress Book*, Milan.